

# Lesion sites that predict the ability to gesture how an object is used

C.J. PRICE<sup>1</sup>, J.T. CRINION<sup>2</sup>, A.P. LEFF<sup>2</sup>, F.M. RICHARDSON<sup>1</sup>, T.M. SCHOFIELD<sup>1</sup>,  
S. PREJAWA<sup>1</sup>, S. RAMSDEN<sup>1</sup>, K. GAZARIAN<sup>1</sup>, M. LAWRENCE<sup>1</sup>, L. AMBRIDGE<sup>1</sup>,  
M. ANDRIC<sup>3</sup>, S.L. SMALL<sup>3</sup>, M.L. SEGHER<sup>1</sup>

<sup>1</sup> Wellcome Trust Centre for Neuro-imaging, Institute of Neurology, University College London, UK;

<sup>2</sup> Institute of Cognitive Neuroscience, University College London, UK;

<sup>3</sup> Department of Neurology, University of Chicago, USA

## ABSTRACT

*We used a two stage procedure to predict which stroke patients would have chronic difficulties gesturing how to use an object when object recognition and hand movements were intact. First, we searched our PLORAS database by behavior and identified 5 patients who had chronic difficulty gesturing object use but no difficulty recognising objects, comprehending words or moving their hands. High definition lesion analyses showed that all 5 patients had damage to the white matter underlying the left ventral supramarginal gyrus, (A) close to the cortex, (B) deep towards the midline and (C) extending into the temporal lobe. In addition, 2 patients had damage to (D) the left posterior middle temporal cortex, and 3 patients had damage to (E) the left dorsal supramarginal gyrus and (F) the left premotor cortex.*

*Second, we searched our database by lesion location for patients who had damage to any part of regions ABCDEF. The incidence of gesturing difficulties was higher in patients with damage to ABCD (7/9), ABCE (7/10) or ABCDE (10/13) than ABCF (7/13), ABC (8/16) or partial damage to ABCF (6/32). Thus behaviour was best predicted by the combination of regions that were damaged (a “network-lesion”) rather than on the basis of each region alone or overall lesion size. Our results identify which parts of the temporal and parietal lobes impair the ability to gesture object use and which parts need to be intact to support it after damage. Our methods provide a framework for future studies aiming to predict the consequences of brain damage.*

## Key words

*Mancano*

## Introduction

Many studies have shown that patients who have difficulty gesturing how to use an object have damage to the left inferior parietal lobe (Leipmann, 1908; Heilman et al., 1982; Rothi et al., 1985; Goodale and Milner, 1992; Leiguarda and Marsden, 2000; Johnson-Frey, 2004; Goldenberg, 2009) but this well established finding has limited clinical use because left inferior parietal damage is not a good

predictor of whether patients will have gesturing difficulties (Goldenberg, 2009). In the current study, we aim to provide anatomically precise descriptions of the lesion sites that impair the ability to gesture how an object is used. These lesion descriptions index the combination of regions that have been damaged and we therefore refer to them as “*network lesions*”. We then compute the probability that each network lesion predicts the ability to produce the same gestures in other patients.

Predicting the consequences of brain damage is notoriously challenging. The prime concern is that damage to the same brain region has inconsistent effects in different patients. The most pessimistic explanation for this inconsistency is that functional anatomy differs across individuals. However, a growing body of functional neuroimaging data acquired in both healthy and brain damaged patients highlight more consistencies than inconsistencies in functional anatomy. For example, in healthy participants, functional object use consistently activates the left posterior middle temporal cortex, the left anterior inferior parietal cortex and the left precentral cortex (Johnson-Frey et al., 2005; Noppeney et al., 2005; Fridman et al., 2006; Buxbaum et al., 2008). A second possible explanation for the inconsistent effects of brain damage is that patients differ in their ability to recover (Lazar and Antoniello, 2008, Prabhakaran et al., 2008). This might reflect differences in treatments or intervention strategies (Van Peppen et al., 2004; Dobkin, 2005). It may also relate to the age of the patient, their ability and motivation to relearn, and differences in the time course of natural recovery processes (Kotila et al., 1984; Stein et al., 2009). A third explanation is that the effect of damage to one region depends on which other regions have also been damaged (Price and Friston, 2002). For example, Goldenberg (2009) has suggested that left inferior parietal damage only impairs object use when there is also additional damage to other left hemisphere regions or the right parietal lobe. In this instance, the effect of lesions will be inconsistent or unpredictable if lesion-behavior mappings focus on single brain regions or voxels (e.g. in univariate, voxel-based lesion-symptom mapping). Nevertheless, predictable and consistent effects of lesions could be identified if behavior were mapped to multivariate lesion measures (e.g. Herskovits and Gerring, 2003; Chen et al., 2008; Chen and Herskovits, 2010) which we refer to here as *network lesions*.

In this study, we combined lesion overlap maps and voxel based morphometry (VBM) to identify the most consistent and significant lesion sites that impaired the ability to generate hand actions associated with everyday objects (e.g. gripping a mug and lifting it and tilting it towards the mouth in order to simulate a drinking action). Specifically, we were looking for the brain regions that link intact object

recognition to intact hand movements for utilizing objects. To focus on this linking process, we excluded patients who had difficulty recognizing objects, moving their hands or understanding and remembering task instructions. To minimize variability that is a consequence of patients being at different stages of recovery, we also excluded patients who were assessed within a year of their stroke. Other inclusion and exclusion criteria are listed in the methods section. Having identified patients on the basis of their behaviour and demographics, we identified the lesion sites associated with impaired performance. Our first lesion analysis used lesion overlap maps to identify the most consistent network of regions that was damaged in patients with known gesturing difficulties. Our second lesion analysis used voxel based morphometry (VBM) to identify where the lesion sites in patients with gesturing difficulties differed from the lesion sites in patients who had difficulty naming actions and repeating heard words but no difficulty gesturing object use. The results of both lesion analyses identified a set of regions that were damaged in patients with gesturing difficulties. To validate and extend these findings, we also conducted a functional magnetic resonance imaging (fMRI) study that identified which brain regions were activated when 20 healthy subjects performed the same task (generating hand actions in response to pictures of everyday objects). As in the lesion study, we aimed to dissociate action retrieval from object recognition and motor output. Together, the results of these three analyses (two lesion and one fMRI) provide a network of candidate regions associated with gesturing how to use objects.

Having identified a network of areas for gesturing, we wanted to test whether damage to this network predicted the presence or absence of gesturing difficulties in other patients. To do this, we needed to reverse the direction of our inference. Rather than identifying the brain areas associated with a known behavior (as in the first three analyses), the fourth analysis determined whether or not gesturing was impaired in other patients from our database who had lesions to the identified network. The probability that known lesion sites were associated with gesturing difficulties could then be assessed and the implications of the results for clinical translation considered. In summary, our investigation of the lesion sites associated with gesturing entailed the following

new aims: (1) to describe the lesions that impair the ability to gesture object use in terms of the network of regions that have been damaged; (2) to test the probability that the identified network lesions cause gesturing difficulties in other patients. Our conclusions are based on the integration of results from lesion analyses and an fMRI study of gesturing in healthy controls. Our methods provide a framework for creating a description of critical lesion sites that can be used as a diagnostic tool to predict the likelihood of impairments after brain damage.

## Methods

Both the lesion and fMRI studies were approved by the joint ethical committee of the Institute of Neurology and the National Hospital for Neurology and Neurosurgery, London, UK. Written informed consent was obtained from all participants.

### *Patient selection on the basis of behaviour*

Patients were selected from the PLORAS database (Price et al., 2010) in three stages. In the first selection stage, we identified all right handed patients who had: a history of stroke (single or multiple); a high resolution T1 MRI brain scan; a left hemisphere lesion that was larger than 1 cm<sup>3</sup>; and a behavioral assessment administered with the Comprehensive Aphasia Test (CAT; (Swinburn et al., 2004). We excluded patients who had other neurological disorders, major psychiatric problems or right hemisphere strokes. Patients with bilateral strokes were included in this initial selection. We also excluded patients who were assessed more than 10 years after their strokes or who were not tested on the gesturing task. This identified 157 patients who we refer to as Selection 1. In the next selection phase, we excluded patients who did not speak English as a native language, were tested within one year of their stroke; and who had difficulties or incomplete data on the tasks involving visual perception, object recognition, written word recognition, auditory speech comprehension, holding instructions in memory. Importantly, we also excluded patients who had poor motor control of their right hand (i.e. a paretic right hand). The tasks used to test these processes are listed in Table Ia. This second selection procedure reduced the number of patients from 157 to 49. In

the third selection stage, we identified which of the 49 patients from the second selection stage had difficulties producing hand movements that illustrated how the object depicted in a color photograph would be used (e.g. comb, scissors, toothbrush). Five patients met all these inclusion and exclusion criteria. Details of the stimuli, instructions and scoring for each task can be found in the Appendix. Details of the performance of these 5 patients can be found in Table II which shows that all the patients who had difficulties on the gesturing task also had difficulties with naming actions, naming objects and animals, reading and auditory repetition. See VBM analysis below for how we segregated lesions causing gesturing difficulties from lesions causing speech production difficulties.

### MRI data acquisition

All patients were scanned either on the same day or within one week of their behavioural testing, using a T1 weighted anatomical whole brain image acquired with a Siemens 1.5 T Sonata MRI scanner (Siemens Medical Systems, Erlangen, Germany). A T1 weighted 3D modified driven equilibrium Fourier transform sequence was used to acquire 176 sagittal slices with an image matrix of 256x224 yielding a final resolution of 1 mm<sup>3</sup>: repetition time/echo time/inversion time, 12.24/3.56/530 ms (Deichmann et al., 2004). The same scanner and scanning parameters were used for the acquisition of all structural images for the lesion study as well as the fMRI study (see below).

### MRI preprocessing

Structural images were preprocessed with Statistical Parametric Mapping software (SPM5: Wellcome Trust Centre for Neuroimaging; <http://www.fil.ion.ucl.ac.uk/spm>) running under MATLAB (MathWorks, Natick, MA, USA). The images were spatially normalized into standard Montreal Neurological Institute (MNI) space using a unified segmentation algorithm optimized for use in patients with focal brain lesions. The unified segmentation algorithm is a generative model that combines tissue segmentation, bias correction and spatial normalization in the inversion of a single unified model (Ashburner and Friston, 2005). This algorithm was developed to deal with normal subjects' brains but is now routinely applied to patient data because it has been shown to be as effective

Table I. - Patient selection on the basis of behavioural tests.						
(a) Excluded if performance impaired on these tasks						
Task - >	Line Bisection	Match P to P	Match P to VW	Match P to AW	Comprehend Paragraph	Write Words
<i>Processing tested</i>						
Visual perception						
Object recognition						
Written word recognition						
Speech perception						
Speech comprehension						
Memory for instructions						
Motor control of the hand						
P = picture; AW = auditory word; VW = visual (written) word.						
(b) Other tests						
Task - >	Hand Gesture	Name Action	Name Object	Reading Aloud	Auditory Repetition	
<i>Processing tested</i>						
Linking objects to actions						
Action Recognition						
Word retrieval						
Articulation						
(c) VBM groups						
VBM Group	1	2	3	4		
Gesturing object use						
Auditory repetition						
Reading aloud						
Action Naming						

as the cost function masking (Crinion et al., 2007). More recently, a modified version of the tissue segmentation component has been developed to further improve identification and spatial normalization of ‘brain’ as opposed to ‘nonbrain’ components by adding in an extra tissue class, ‘lesion’, into which outlier voxels can be classified (Seghier et al., 2008). The grey and white matter images were then smoothed with an isotropic kernel of 8 mm at full width half maximum to increase the chance that regional effects are expressed at a spatial scale in which homologies in structural anatomy are shared over subjects. After smoothing, the value in each voxel represents the probability that the tissue belongs to the grey or white matter class and is not nonbrain or lesion). The lesion of each patient was automatically identified using an outlier detection algorithm based on fuzzy clustering (Seghier et al., 2007) with default parameter settings

(see procedure in Seghier et al., 2008). An outlier image was thus generated that coded the degree of abnormality of each voxel (i.e. how far the value at a given voxel is from the normal range of 64 healthy controls) as a continuous measure varying from 0 for an intact voxel to 1 for a completely damaged voxel. We refer to these images as fuzzy lesion images (the word “fuzzy” is borrowed from the fuzzy clustering algorithm cited above). Each fuzzy lesion image was also thresholded to create a binary image. All images were generated into the MNI space for group analyses. Fuzzy images were used in the VBM analysis and binary images were used in the lesion overlaps (see analyses sections below).

#### *fMRI experimental design*

Full details of this study can be found in (Richardson et al., 2010). The number of participants was less

Table II. - Details of the 5 patients in whom the initial lesion sites were identified.

Patient ID	P1	P2	P3	P4	P5
Age at scan (years)	69.5	43.2	74.9	60.1	50.6
First Language	English	English	English	English	English
Handedness	Right	Right	Right	Right	Right
Gender	M	F	M	F	M
Months between stroke and scan	19	95	332	100	42
Gap between CAT and scan (days)	0	0	0	0	0
Lesion hemisphere	Left	Left	Left	Left	Left
Total volume (2 mm <sup>3</sup> voxels)	3207	9714	19126	47457	48155
<b>Performance on CAT measured in T scores. Impaired scores are white on grey</b>					
Gesturing object use	47	47	42	43	47
Auditory word comprehension	55	53	55	55	58
Written word comprehension	59	55	59	59	55
Auditory paragraph comprehension	60	60	60	60	49
Line Bisection	48	59	53	44	53
Copy writing	61	61	61	61	61
Semantic memory	60	51	60	60	60
Recognition memory	48	59	59	59	59
<b>Other tasks</b>					
Name action in picture	59	50	52	54	54
Name objects and animals	64	52	55	61	37
Auditory word repetition	46	56	46	51	43
Reading single words	53	51	60	57	45
Verbal Fluency	62	52	61	57	45
Digit Span	55	46	50	59	43
Written sentence comprehension	65	54	60	60	57
Auditory sentence comprehension	63	51	54	58	52
Auditory repetition of sentence	63	48	63	53	48
Auditory dictation (spelling)	59	50	57	57	44
Arithmetic	65	65	65	53	57

in the current study because we excluded those in whom data acquisition did not include the dorsal parietal regions and the cerebellum. The 20 participants who contributed to the current results were all healthy and right handed (8 males) with a mean age of 27 years (range 13 to 73). They all spoke English as their first language, had normal or normal corrected vision, with no reported hearing, language or reading difficulties.

The experimental paradigm included four different “mini experiments” that were interleaved within and across four different scanning runs. The mini experiment that is relevant to the present study involved the retrieval and production of hand actions in response to pictures of familiar objects that had

strongly associated hand actions, e.g., *scissors*, *spoon* and *calculator*. For consistency with the lesion study reported below, we refer to this task as “gesturing object use”. Participants were instructed to make the corresponding hand movement/gesture with their right hand. In the baseline tasks, participants viewed pictures of familiar objects that did not have strongly associated hand actions (e.g. barrel). They were instructed to make a rocking motion with their right hand in response to viewing these stimuli. Responses were recorded using a video camera, directed on the right hand of the participant in the scanner. Across the experiment, there were 12 blocks of gesturing object use and 12 blocks of the baseline conditions. Within each 18 second block,

there were 15 pictures with an event duration of 0.5 s and an ISI of 0.7 s. The presentation of stimuli was set at this rate in order to limit object naming and to allow participants to complete their hand action before the onset of the next stimulus.

### *fMRI Data Acquisition*

A Siemens 1.5T Sonata scanner was used to acquire a total of 768  $T_2^*$  weighted echoplanar images with BOLD contrast (192 scans per 4 sessions). Each echoplanar image comprised 30 axial slices of 2 mm thickness with 1 mm inter slice interval and 3 x 3 mm in plane resolution. Volumes were acquired with an effective repetition time (TR) of 2.7 s/volume and the first six (dummy) volumes of each run were discarded in order to allow for T1 equilibration effects. In addition, a T1 weighted anatomical volume image was acquired from all participants to ensure that there were no anatomical abnormalities. Details of the acquisition sequence were the same as those used in the Lesion study (see above for details).

### *fMRI preprocessing*

As described in (Richardson et al., 2010), we used standard SPM procedures including movement correction, spatial normalisation to the standard MNI template and spatial smoothing with a 6 mm full width half maximum isotropic Gaussian kernel. The first level statistical analysis included high pass filtering using a set of discrete cosine basis functions with a cut off period of 128 seconds and each stimulus was modelled as a separate event within each condition and convolved with a canonical hemodynamic response function (HRF). For the current study, the contrast of interest was the comparison of (1) Gesturing object use relative to viewing familiar objects while making hand movements that are unrelated to the object.

### **The four analyses referred to in the results section**

#### *1. Using lesion overlap maps to identify the most consistent lesion sites for known behavior.*

The binary images for each of the five patients with difficulty gesturing how an object was used despite intact performance on many other tasks (listed in Table 1a) were overlapped (i.e. summed across subjects) to generate a lesion overlap map (Frank et

al., 1997). Therefore, at each voxel across the entire brain, the lesion overlap map indicates the number of patients who have a lesion. The MNI coordinates of areas with maximum lesion overlap are easily extracted along with the identity of the patients with these lesions. This analysis was carried out with scripts written in Matlab that were incorporated in SPM5 as a Toolbox. Because of (i) the limited number of patients and (ii) the difficulty to define an unbiased threshold on the lesion overlap maps (see Rudrauf et al., 2008), we only consider here voxels that have been damaged in all 5 patients.

#### *2. Using VBM to identify the most significant association of lesion site to known behaviour.*

To characterize how lesion sites differed in the patients who did and did not have difficulties gesturing the use of objects, we used voxel based morphometry (VBM) which is a whole brain, unbiased, semi automated technique for characterizing regional differences in structural magnetic resonance images (Ashburner and Friston, 2000). Statistical analyses were performed on the fuzzy lesion images using the general linear model as implemented in SPM5. Covariance structure (for REML algorithm) was set to be independent with unequal variance in different groups. The advantages of using the fuzzy lesion images rather than grey or white matter images as in our previous patient studies (Gitelman et al., 2000; Noppeney et al., 2005; Leff et al., 2009), is that the fuzzy lesions combine grey and white matter into one image; and reduce error variance in the estimation of abnormality because they are based on a prior comparison to 64 healthy controls (see Seghier et al., 2008).

Our VBM analysis included 4 groups of participants who had intact performance on tests of object recognition, word comprehension and hand movements (see Table 1a). The VBM groups were based on the patients' ability to produce hand actions or spoken speech (see Tables 1b and 1c). The first group included our 5 patients of interest who had difficulties with all types of production task. The second group ( $n = 8$ ) had difficulties with speech production tasks (object naming, repetition and reading) but not gesturing how an object was used. The third group ( $n = 9$ ) was only impaired in action naming; and the fourth group ( $n = 21$ ) did not have difficulty with any of the production tasks. The VBM design matrix partitioned the fuzzy

lesion images for our four patient groups using a one way ANOVA. The statistical contrast of interest was the difference between Group 1 and Group 2 because (a) only Group 1 had difficulties on the gesturing task and (b) Group 2 controlled for difficulties with speech production. We then compared the lesion sites identified in Group 1 to those in all other groups to confirm that the identified effects were specific to the patients with gesturing difficulties. We only report and discuss regions that showed significant positive effects at  $p < 0.05$  after correction for multiple comparisons across the whole brain at the height (voxel) or cluster level. We acknowledge three conceptual issues when interpreting the VBM results. First, significant effects can be driven by a few subjects, particularly when the sample sizes are small. Second, consistent lesions in one group will not necessarily be identified if patients in other groups have similar lesions. Third, lesion data do not necessarily meet the assumptions of normality that are required for standard parametric tests (Kimberg et al., 2007; Rorden et al., 2007; Rorden et al., 2009); but see (Medina et al., 2010) for small group sizes). Hence, we decided to report three different lesion analyses.

### *3. fMRI study of healthy participants to validate and extend lesion analysis.*

The 20 subject specific contrast images (parameter estimates) from the first level analysis were entered into a second level t test. This identified activation at the group level for gesturing object use relative to viewing familiar objects while making hand movements that are unrelated to the object. The statistical threshold for significant effects was set at  $p < 0.05$  after correcting for multiple comparisons across the whole brain in either height (family wise correction) or extent.

### *4. The probability that a known lesion site causes a behavioural deficit.*

We created a lesion overlap map of all patients from Selection 1 ( $n = 157$ ) and extracted the identity of all patients who had a lesion at each of the regions associated with gesturing difficulties in Analyses 1 to 3. Each patient was given a 1 to 6 letter code (e.g. ABCDEF or F or CD) to indicate which regions were damaged. The patients were then grouped according to these network lesion codes (i.e. patients in the same group had an identical combination of damaged regions). The

probability of gesturing difficulties was computed for each network lesion as: the number of patients with the same network lesion and object gesturing difficulties, divided by the total number of patients with the same network lesion. We then compared the predictive validity of the different network lesions.

## Results

### *1. Using lesion overlap maps to identify the most consistent lesion sites for known behaviour.*

The lesion overlap map for the 5 patients who had difficulties gesturing in the context of good object recognition, word comprehension and hand movements illustrated that all 5 patients had damage to white matter underlying the left ventral supramarginal gyrus, (A) close to the cortex, (B) deep towards the midline and (C) extending into the temporal lobe, see Fig. 1 and Table III.

### *2. Using VBM to identify the most significant association of lesion site to known behaviour.*

Three regions were found to be more damaged in the patients with difficulties gesturing how an object was used (VBM Group 1) than all other groups. These were anatomically located in the left posterior middle temporal cortex (henceforth area D), left dorsal supramarginal gyrus (henceforth area E), and left premotor cortex (hence forth area F), see Table III and Fig. 2 (blue coloured regions). These areas were not identified in the lesion overlap map because they were not consistent across all 5 patients. They were driven by 2 patients who had damage to E and F, 1 patient who had damage to D; and 1 patient who had damage to D, E and F. The fifth patient did not have damage to any of these three areas. Thus the lesion sites that were consistent across patients (ABC) in the lesion overlap map were not the same as the lesions that discriminated between patients (D, E and F) in the VBM analysis.

### *3. fMRI study of healthy participants to validate and extend lesion analysis.*

The areas activated for gesturing object use relative to viewing pictures of objects and making unrelated hand movements were the left posterior middle temporal cortex (D), left dorsal supramarginal gyrus (E), left premotor cortex (F) and bilateral cerebellum, see

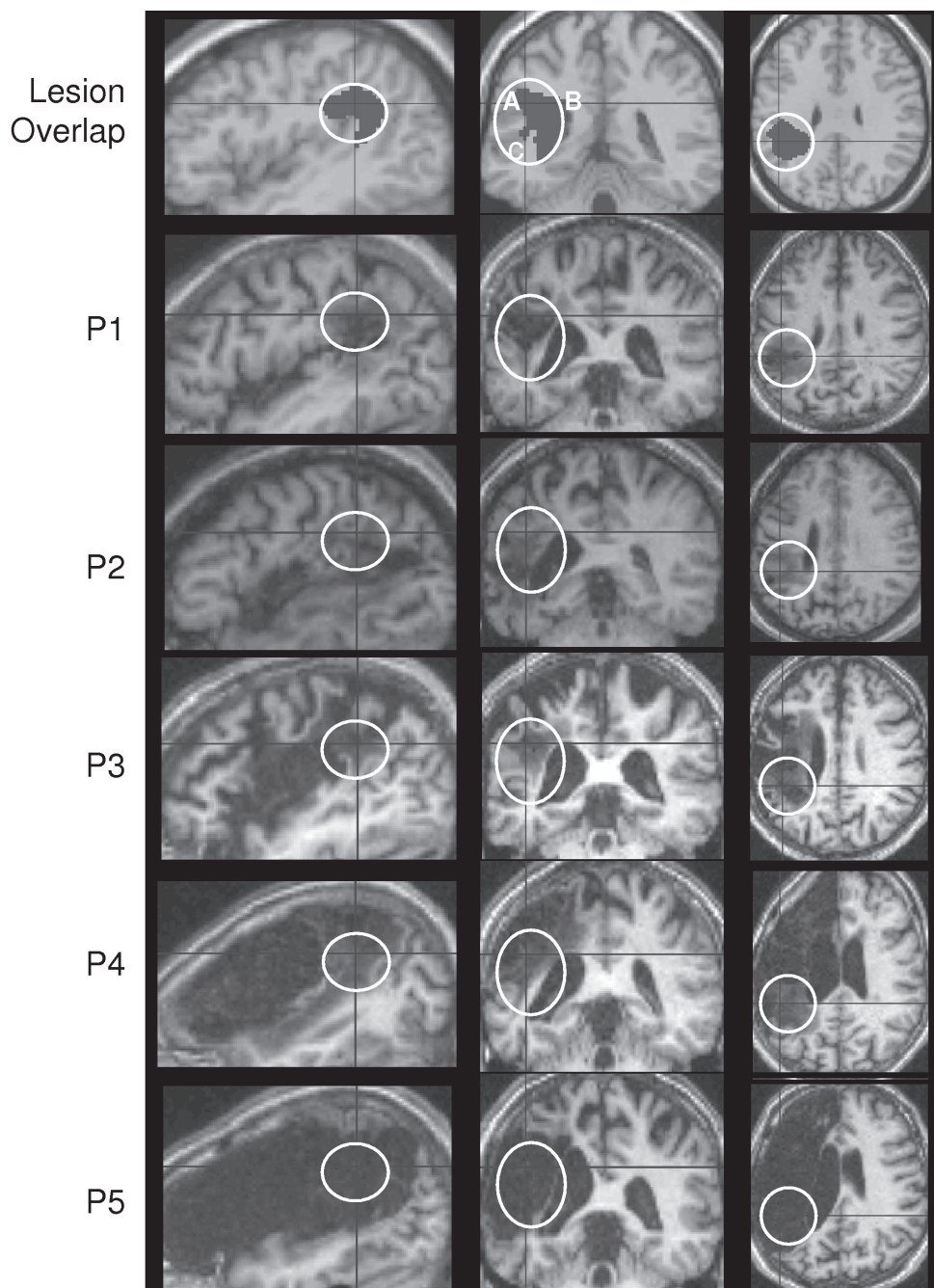


Fig. 1. - Lesion sites in the 5 patients (P) of interest with gesturing difficulties.

Table III. These activations (see yellow regions in Fig. 2) were in remarkably close proximity to those identified in the VBM analysis (see blue regions in Fig. 2) but only overlapped in areas D and F. This may be because the fMRI study was (i) limited to grey matter activations; (ii) more sensitive to effects in grey matter because of increased subject numbers and because lesion analyses are very dependent on

the patient sampling (Rorden et al., 2007; Rudrauf et al., 2008; Rorden et al., 2009).

#### 4. The probability that a known lesion site causes a behavioural deficit.

Of the 157 patients from Selection 1, 107 had damage to at least one of the regions identified in Analyses 1 to 3. The combination of regions that

Table III. - Areas damaged in those with gesturing difficulties.

Region	Location	Lesion overlap MNI	VBM MNI	fMRI MNI
A	Temporo-parietal WM	-36 -47 19		
B	L. ventral supramarginal WM	-42 -38 30		
B		-36 -42 25		
C	L. medial WM tracts	-24 -24 30		
C		-24 -45 28		
D	L. post. middle temporal		-52 -50 -4	-52 -66 -4
E	L. dorsal supramarginal gyrus	-50 -50 40	-32 -44 44	
			-48 -46 52	-40 -40 52
			-50 -40 44	
				(-46 -24 52)
F	L. premotor cortex		-44 8 26	-46 4 26
				-54 8 24
				-54 6 40
	L. Cerebellum			-22 -54 -22
	R. Cerebellum			+24 -54 -20

were damaged in each patient was classified by a network lesion code. Three of these patients had damage to the left cerebellar area that was activated in the fMRI study. All three of these patients had object gesturing difficulties. Of the remaining 104 patients, 61 had damage to all of ABC and 43 had damage to some of ABC. There were no patients who had selective damage to the grey matter regions D only, E only, F only or any combination of D, E, F in the absence of damage to the white matter (ABC). The incidence of object gesturing difficulties was significantly higher ( $Z = 3.6$ ) in those with damage to all of ABC ( $39/61 = 64\%$ ) than those with partial damage to ABC ( $12/43 = 28\%$ ). There was no impact on object gesturing when there was additional damage to area F in those with damage to ABC but not D or E ( $7/13 = 54\%$  with F versus  $8/16 = 50\%$  without F) and those with partial damage to ABC but not D and E ( $1/6 = 17\%$  with F versus  $5/26 = 19\%$  without F). However, the incidence of object gesturing difficulties increased ( $75\%$ ) in those with damage to ABCD ( $7/9$ ), ABCE ( $7/10$ ) or ABCDE ( $10/13$ ), see Table IVa.

These results are not simply a consequence of lesion size because large lesions did not cause gesturing difficulties if they spared some of the ABCDE areas we associate with gesturing (see Table IVb). Moreover, the size of the lesions in our 5 patients

of interest varied from relatively small to very large, see Fig. 1. Those with larger lesions had difficulties on other language tasks such as digit span and sentence comprehension in addition to their difficulties producing gestures and speech but these co occurring impairments are not the focus of the current study.

## Discussion

In this study, we investigated the lesion sites associated with difficulties gesturing object use when object recognition and the ability to make hand movements are intact. By focusing on a very specific behavioural impairment, we hoped to identify a very specific lesion site. However, we found that all 5 of the selected patients also had difficulty naming the action that a person was performing on an object; repeating heard words; and reading aloud; 4/5 patients also had difficulty naming the object itself. Thus, their impairment is at the level of linking object (or word) recognition to either manual or verbal responses. To isolate areas involved in gesturing object use from areas that support name retrieval, we compared the lesion sites in patients with object gesturing and naming difficulties to the

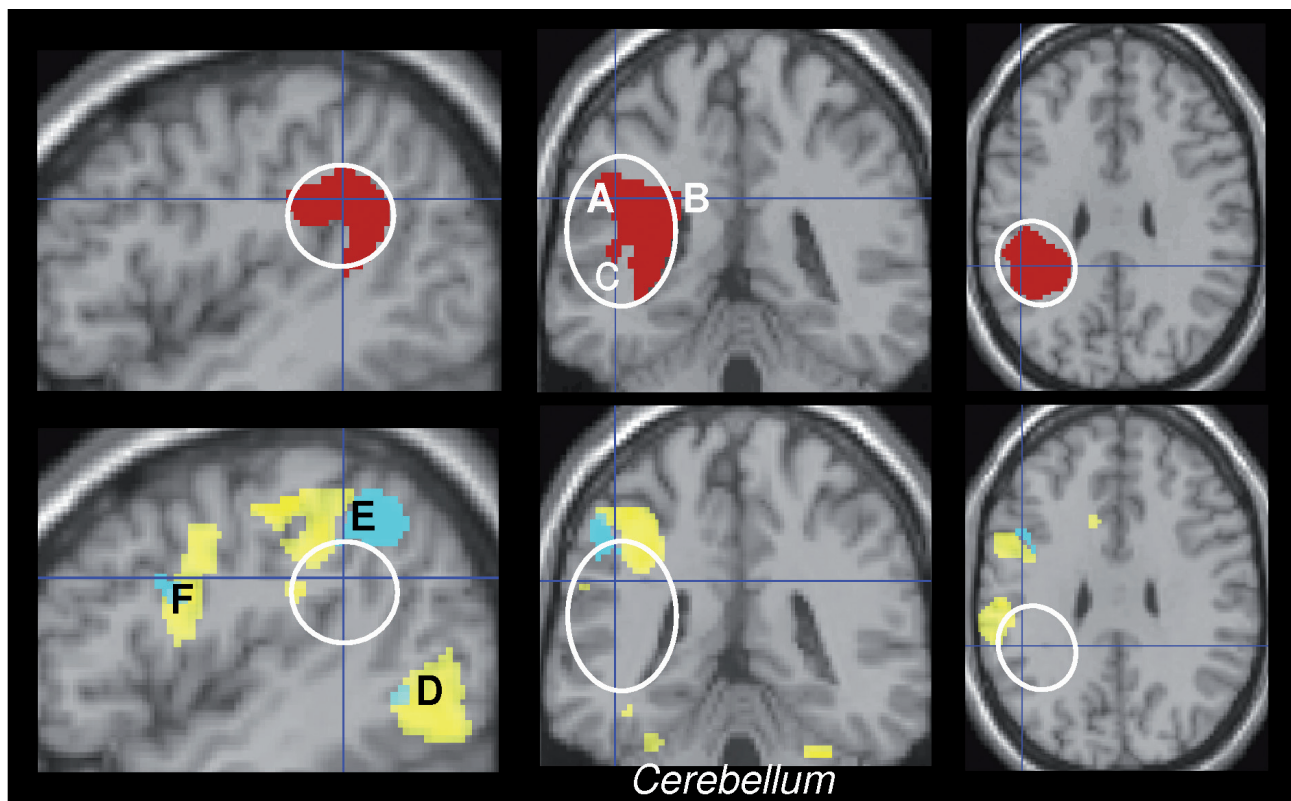


Fig. 2. - Lesion overlap map (red), VBM (blue) and fMRI (yellow).

lesion sites in patients with object naming but not object gesturing difficulties.

A lesion overlap map and VBM were used to identify the most consistent and significant lesion sites. The lesion overlap map identified extensive left temporo-parietal white matter damage (ABC) in all 5 patients. The VBM analysis found that, relative to patients with object naming but not object gesturing difficulties, patients with object gesturing difficulties had more damage in the left posterior temporal cortex (region D), the left dorsal supramarginal gyrus (region E) and the left premotor cortex (region F). These regions were not identified in the lesion overlap map because they were not damaged in all 5 patients. They were driven by 2 patients who had damage to E and F, 1 patient who had damage to D; and 1 patient who had damage to D E and F. The fifth patient did not have damage to D or E or F. Thus, the lesion overlap map identified lesion sites that were consistent across patients, and the VBM analysis identified lesion sites that discriminated object gesturing from naming difficulties. Together the results identify a set of brain regions for gestur-

ing that included 7 left hemisphere regions: 3 in the temporal and parietal white matter that were associated with gesturing and naming, 3 in temporal, parietal and frontal grey matter that were specific to gesturing and one in the cerebellum.

How consistent are the gesturing regions identified by our lesion analyses with the gesturing regions identified in the fMRI study of healthy subjects? The answer to this question is illustrated in Fig. 2. This shows that the grey matter regions identified by VBM in the left posterior middle temporal (D), left dorsal supramarginal gyrus (E) and left premotor cortex (F) neighbour those activated when healthy subjects are gesturing the use of objects but with minimal overlap. The fMRI results indicate where grey matter activation is highest. In contrast, the VBM analysis is (a) sensitive to the white matter connections that are essential for relaying information between the grey matter regions; and (b) biased by sampling of the lesion sites in our patient population (Rorden et al., 2007). In addition, it should also be noted that neither the fMRI nor the VBM identified the importance of the white matter tracts

Table IVa. - Incidence of Gesturing impairments in patients with damage to ABCDEF						
Damage to:	no DEF	with F	with D	with E	with DE	Total
<i>All ABC</i>						
Impaired	8	7	7	7	10	39
Total	16	13	9	10	13	61
%	50%	54%	78%	70%	77%	64%
<i>Partial ABC</i>						
Impaired	5	1	2	4	0	12
Total	26	6	5	6	0	43
%	19%	17%	40%	67%		28%

Table IVb. - Lesion size in patients with and without gesturing difficulties (lesion size assessed from the binary lesion images; volume per voxel = 0.008 cm <sup>3</sup> ).								
Patients	Size (in voxels)							
	100-5k	5-10k	10-15k	15-20k	20-30k	30-40k	40-50k	50-60k
5 patients of interest	1	1		1			2	
Gesturing impaired	13	16	7	7	9	3		1
Gesturing OK	16	18	13	8	6	2		

seen in the lesion overlap map. In the case of fMRI this is because there is no detectable activation in the white matter. In the case of VBM, it is because the same areas of white matter (ABC) are lost in other patients who do not have gesturing difficulties. Thus, the characterization of the network of regions that support gesturing required the integration of results from different analyses, as illustrated here with a lesion overlap map, VBM of patient data, and fMRI of healthy subjects.

The network of regions that we associate with object gesturing difficulties and/or gesturing activation is consistent with prior studies. The importance of the left inferior parietal lobe is well established (see Goldenberg, 2009 for a review). All three grey matter regions (DEF) have been identified in previous functional imaging studies requiring action retrieval (Ohgami et al., 2004; Johnson-Frey et al., 2005; Noppeney et al., 2005; Fridman et al., 2006; Buxbaum et al., 2007; Bohlhalter et al., 2009), and recently it has been shown that grey and white matter density in the left posterior temporal lobe (D), left anterior inferior parietal lobe (D) and the cerebellum increases in monkeys learning to use a tool (Quallo et al., 2009). Therefore, we are confident that the network of areas that our lesion and fMRI analyses identified provide a good description of the set of regions that will predict gesturing difficulties

in unstudied populations of patients. It may also be of interest to note that none of our analyses identified the left inferior frontal cortex. This may reflect the fact that left inferior frontal activation is more associated with the ability to recognise than produce gestures (Tranel et al., 2003; Buxbaum et al., 2005; Skipper et al., 2007; Pazzaglia et al., 2008; Dick et al., 2009; Nelissen et al., 2010).

Having identified a network of regions for gesturing, we turn to the more important question: Can we predict whether other patients with damage to this system will have difficulties gesturing the use of objects? To do this, we have to reverse the direction of our inference. Rather than investigate the lesion sites in patients selected on the basis of a known behavioural deficit, we need to investigate whether or not patients have gesturing difficulties in the context of known lesions to the network. To do this, we categorized 157 patients with a 1 to 6 letter network lesion code (e.g., ABCDEF or F or CD) that indicated which combination of regions had been damaged. For each network lesion code, we calculated the number of patients who did and did not have object gesturing difficulties. This allowed us to estimate the probability that each lesion site impaired gesturing. Before discussing the results, we note that the probability of impaired gesturing is likely to be over estimated when all 157 patients

are considered. This is because, in this larger sample of patients, gesturing difficulties could be a consequence of difficulties in object recognition, comprehension or hand movements that are due to concurrent damage in other brain regions. The most informative results therefore pertain to the preservation of gesturing despite damage to regions involved in gesturing, object recognition, comprehension or hand movements.

The network lesion with the lowest likelihood of preserved object gesturing, defined as one minus the probability of gesturing difficulties (Table IVa), was characterized by damage to all of ABCD (22%). The second lowest likelihood of preserved gesturing (30%) was associated with damage to ABCE. In contrast, damage to regions ABC without D or E was associated with a 50% chance of preserved gesturing; and damage to part of ABC (not D or E) was most likely (82%) to preserve gesturing. Damage to region F (the premotor area) had no impact on the incidence of gesturing difficulties. Together, these results illustrate that gesturing difficulties are more likely when there is damage to the grey matter regions D or E in addition to the parietal white matter (ABC). Critically, it was not the size of the lesion that matters but the combination of regions that are damaged. In other words, the effect of damage to one region depends on whether other regions of the same system have also been damaged.

This leads us to the next important question: How are patients able to preserve or recover the ability to gesture following damage to the gesture network? To answer this question, we need to determine whether gesturing can be supported by areas that have not been identified in the current study or by a reduced set of regions (e.g., if damage to one region can be compensated for by increased reliance on the remaining regions). We could identify the compensatory mechanisms by conducting fMRI studies of patients who have recovered from gesturing difficulties or who are at progressive stages of recovery. We could also continue to explore the current set of data to investigate other factors that predict which patients did and did not have gesturing difficulties as well as the severity of their gesturing impairment. These other factors might relate to demographic variables (e.g. time since stroke), cognitive variables (e.g. working memory capacity) or the identification of other lesion sites that might have been missed in the

current analysis. However, such exploratory analyses become increasingly time consuming and complex, particularly as the number of brain regions being analyzed increases (see Kenny et al., 2009 for an approach aimed at solving such issues). They therefore require the use of less constrained multivariate lesion analyses as have been applied in other studies (e.g. Herskovits and Gerring, 2003; Chen et al., 2008; Friston et al., 2008; Chen and Herskovits, 2010).

The success of the current and future analyses is also limited by the number of patients that can be included. Here, we note that, even with 157 patients who met our first set of selection criteria, the sample of lesion sites was not complete. For example, we do not have any patients in our database who have grey matter lesions to the left posterior middle temporal cortex or the left dorsal supramarginal gyrus that do not also include the underlying white matter. Indeed, such patients may never exist. In this case, the only way to segregate the impact of grey matter lesions is to compare white matter lesions that do and do not include adjacent grey matter. The predictive validity of our conclusions would, nevertheless, be improved with higher patient numbers and increased diversity in the lesion sites. It is for this reason that the PLORAS database has been developed and opened up for widespread collaboration (see Price et al., 2010). With increased patient numbers, lesion diversity and the necessary developments in network lesion analyses, we are optimistic that our ability to predict the consequences of brain damage will improve rapidly in the next few years. For the time being our paper provides proof of concept for the procedures.

In conclusion, we have identified a set of 6 left hemisphere regions that were damaged in patients who had difficulty gesturing the use of objects. Three of these regions were in the temporoparietal white matter (ABC) and two were grey matter regions in the (D) posterior middle temporal, and (E) dorsal inferior parietal lobes. In addition, bilateral cerebellum was activated in the fMRI analysis when healthy subjects gestured object use (Table III) and a reanalysis of our patients from Selection 1 revealed that damage to the left cerebellum was consistently associated with gesturing difficulties in all 3 patients.

More importantly, we investigated how well we could predict gesturing difficulties on the basis of

the identified network lesions. This demonstrated that the ability to gesture was most impaired when parietal white matter damage extended into the left posterior middle temporal and left dorsal supramarginal gyrus. The set of procedures employed in this study may therefore be useful for other studies that aim to predict how patients will recover from sensory motor or cognitive loss after brain damage.

## Appendix

### *Behavioural assessments*

#### **Hand gestures illustrating how an object is used**

Patients were shown a color photograph of the object: pen (practice), peg, comb, mug, scissors, toothbrush, paintbrush and given the verbal instruction “I want you to imagine that I’ve put this object in your hand. Show me how you would use it”. Where needed to aid comprehension, this verbal instruction was supported by a gesture of picking the object off the page and putting it in the patient’s hand. If they still failed this practice item, the gesture was demonstrated. No further instructions were given during the administration of this subtest. Patients scored 2 marks per item for correct gesture with no ambiguity; 1 mark for incorrect action or orientation or body part used as object; 0 marks if completely incorrect. Errors tended to be incomplete actions that were not uniquely associated with the object in the pictures.

#### **Name objects**

Patients were presented with twenty four black and white line drawings, one at a time, with instructions to verbally name the object in the drawing. Correct items, promptly named, were given a score of 2; 1 mark was awarded if the subject correctly named the item after a delay (5 s) or self corrected; 0 marks if completely incorrect. Administration of the subtest was discontinued after scores of 0 on 4 consecutive test items.

#### **Name actions**

Patients were shown a picture of an action being performed, for example, a picture of a man eating an apple (practice item), a hand touching the dial on the watch, a man sawing a piece of wood, a man thread-

ing a needle, a lady typing on a typewriter, a lady with her tongue touching (licking) a stamp. Patients were given the verbal instruction “Tell me what the person is doing”. No prompts were given except on the practice item where verbal prompts were given as necessary (e.g. “*Tell me what he is doing? He’s*” (pause) “*the apple*” and/or gestural, e.g. miming biting an apple). If the patient still failed to give the correct response, the missing verb (“*eating*”) was given verbally. Such cues were not given during the testing phase. Correct naming responses spoken within 5 seconds, were given a score of 2; 1 mark was awarded where the patient correctly named the item after a delay (5 s) or self corrected; 0 marks if completely incorrect i.e. target verb not generated verbally by patient.

#### **Auditory word repetition**

Patients heard a series of single auditory words (syllable range 1 to 3) and were asked to reproduce the same word of each word. There were 16 items. Verbal, phonemic, neologistic and dyspraxic errors were marked as incorrect. Dysarthric distortions were permissible provided it was clear that the phonemes had been correctly selected from the lexicon.

#### **Reading Aloud**

As for auditory repetition except that the stimuli were 24 written words that did not correspond to those produced during auditory repetition.

#### **Matching pictures of objects to auditory words (P-AW)**

In this test of spoken word comprehension, patients heard a single object name and were visually presented with four black and white line drawings of objects. The instruction was to point to the drawing that corresponded to the word heard. There was one target drawing with three different types of distractor that were either (i) phonologically related to the target, (ii) semantically related to the target or (iii) unrelated to the target. Patients scored 2 marks if they pointed to the correct target; 1 mark when the patient pointed to the correct target after a delay (5 s), requested repetition of the stimulus or self correction; 0 marks if completely incorrect. Thus, to perform this task, the patient had to follow verbal instructions, comprehend single words, recognize drawings of objects and select the correct response and manually point to the selected item.

### Matching pictures of objects to visual (written) words (P-VW)

Same task as above (with different exemplars), but stimulus word was presented in written form.

### Matching pictures of objects to pictures of semantically related objects (P to P)

Patients were visually presented with an image in the centre of a page surrounded by 4 other images. All images were black and white line drawings. Patients were instructed to point to the drawing that “goes best with” i.e. is most closely semantically related to the target object (e.g. ‘Hand’). A gesture was given to support the concept of the pictures being related, where necessary. One of the 4 drawings was a good semantic match to the target (e.g. ‘Mitten’), one was a close semantic distractor (e.g. ‘Sock’), one more distantly related (e.g. ‘Jersey’) and one was unrelated (e.g. ‘Lighthouse’). 1 mark was awarded for each correct response. Successful performance on this task indicated that the patient had recognised the picture and accessed detailed semantic associations.

### Spoken paragraph comprehension

In this task, patients were given the instruction “I’m going to read you a short story. I want you to listen then answer some questions. You should only respond ‘yes’ or ‘no’”. Patients were shown a page with the words “Yes” and “No” printed in larger font. Patients were first read a ‘story’ that was 3 sentences long, then verbally asked 4 yes/no questions relating to information given in the story. Patients were then read a second ‘story’ (unrelated to the first) 4 sentences long, again followed by 4 verbal yes/no questions. Answering appropriately relied on understanding the information given. To check for comprehension – each question was asked twice, one when it required a yes answer and once when it required a no answer. e.g. patients were asked “Were they on time?” and later “Were they early?”. Both questions had to be answered correctly in order for patients to be awarded 1 mark; 0 marks were awarded when only 1 question within a pair was answered correctly. Patients were asked 8 questions in total, with a maximum score of 4 marks. The patients therefore had to comprehend spoken paragraphs and remember and maintain verbal information for the duration of this subtest.

### Line bisection

Patients were presented with a piece of paper on which there were three straight horizontal lines of differing lengths on different parts of the page. Patients were asked to use a pen to make a mark on each line to cut the line into two halves. The accuracy of each bisection was measured by the difference between the mark made and the true mid point. This task tested whether the patient had any signs of visual neglect.

### Writing words and letters

Patients were given a sheet of paper on which there were some upper case letters, some lower case letters and three lower case words. Patients were asked to write down all the letters and words in capital letters: in some cases this only required copying, whilst in others it also required conversion from lower to upper case. 1 mark was allocated for each correct letter written down; 0 marks were received for lower case or otherwise incorrect responses.

### Acknowledgments

This work was funded by the Wellcome Trust and the James S. MacDonnell Foundation (conducted as part of the Brain Network Recovery Group initiative). We would like to thank Amanda Brennan, Janice Glensman, David Bradbury, Anna Isherwood, Alice Grogan, Julie Stewart, Sharon Adjei, Nikki Wilson, Erin Carroll and Katharine Bowers for their help collecting the data.

### References

- Ashburner J. and Friston K.J. Voxel-based morphometry - the methods. *Neuroimage*, **40**: 1429-14235, 2000.
- Ashburner J. and Friston K.J. Unified segmentation. *Neuroimage*, **26**: 839-51, 2005.
- Bohlhalter S., Hattori N., Wheaton L., Fridman E., Shamim E.A., Garraux G., et al. Gesture subtype-dependent left lateralization of praxis planning: an event-related fMRI study. *Cereb. Cortex*, **19** (6): 1256-1262, 2009.
- Buxbaum L.J., Kyle K., Grossman M., Coslett H.B. Left inferior parietal representations for skilled hand-object interactions: Evidence from stroke and corticobasal degeneration. *Cortex*, **43**: 411-423, 2007.

- Buxbaum L.J., Kyle K.M., Menon R. On beyond mirror neurons: internal representations subserving imitation and recognition of skilled object-related actions in humans. *Cogn. Brain Res.*, **25**: 226-239, 2005.
- Buxbaum L.J., Kyle K., Grossman M., Coslett H.B. Left inferior parietal representations for skilled hand-object interactions: evidence from stroke and corticobasal degeneration. *Cortex*, **43** (3): 411-423, 2007.
- Buxbaum L.J., Kyle K.M., Tang K., Detre J.A. Neural substrates of knowledge of hand postures for object grasping and functional object use: evidence from fMRI. *Brain Res.*, **1117** (1): 175-185, 2006.
- Buxbaum L.J., Sirigu A., Schwartz M.F., Klatzky R. Cognitive representations of hand posture in ideomotor apraxia. *Neuropsychologia*, **41**: 1091-1113, 2003.
- Chen R. and Herskovits E.H. Voxel-based Bayesian lesion-symptom mapping. *Neuroimage*, **49**: 597-602, 2010.
- Chen R., Hillis A.E., Pawlak M., Herskovits E.H. Voxelwise Bayesian lesion-deficit analysis. *Neuroimage*, **40**: 1633-1642, 2008.
- Crinion J., Ashburner J., Leff A., Brett M., Price C.J., Friston K.J. Spatial normalization of lesioned brains: Performance evaluation and impact on fMRI analyses. *Neuroimage*, **37**: 866-875, 2007.
- Deichmann R., Schwarzbauer C., Turner R. Optimisation of the 3D MDEFT sequence for anatomical brain imaging: technical implications at 1.5 and 3 T. *Neuroimage*, **21**: 757-767, 2004.
- Dobkin B.H. Rehabilitation after stroke. *N. Engl. J. Med.*, **352**: 1677-1684, 2005.
- Frank R.J., Damasio H., Grabowski T.J. Brainvox: an interactive, multimodal visualization and analysis system for neuroanatomical imaging. *Neuroimage*, **5**: 13-30, 1997.
- Fridman E.A., Immisch I., Hanakawa T., Bohlhalter S., Waldvogel D., Kansaku K., et al. The role of the dorsal stream for gesture production. *Neuroimage*, **29**: 417-428, 2006.
- Friston K.J., Chu C., Mourão-Miranda J., Hulme O., Rees G., Penny W., et al. Bayesian decoding of brain images. *Neuroimage*, **39**: 181-205, 2008.
- Goldenberg G. Apraxia and the parietal lobes. *Neuropsychologia*, **47**: 1449-1459, 2009.
- Goodale M.A. and Milner A.D. Separate visual pathways for perception and action. *Trends Neurosci.*, **15** (1): 20-25, 1992.
- Heilman K.M., Rothie L.J., Valenstein E. Two forms of ideomotor apraxia. *Neurology*, **32**: 342-346, 1982.
- Herskovits E.H. and Gerring J.P. Application of a data-mining method based on Bayesian networks to lesion-deficit analysis. *Neuroimage*, **19**: 1664-1673, 2003.
- Johnson-Frey S.H. The neural bases of complex tool use in humans. *Trends Cogn. Sci.*, **8** (2): 71-78, 2004.
- Johnson-Frey S.H., Newman-Norlund R., Grafton S.T. A distributed left hemisphere network active during planning of everyday tool use skills. *Cereb. Cortex*, **15** (6): 681-695, 2005.
- Kenny S., Andric M., Boker S.M., Neale M.C., Wilde M., Small S.L. Parallel workflows for data-driven structural equation modeling in functional neuroimaging. *Front. Neuroinformatics*, **3** (34): 1-11, 2009.
- Kimberg D.Y., Coslett H.B., Schwartz M.F. Power in voxel-based lesion-symptom mapping. *J. Cogn. Neurosci.*, **19**: 1067-1080, 2007.
- Kotila M., Waltimo O., Niemi M.L., Laaksonen R., Lempinen M. The profile of recovery from stroke and factors influencing outcome. *Stroke*, **15**: 1039-1044, 1984.
- Lazar R.M., Antonietto D. Variability in recovery from aphasia. *Curr. Neurol. Neurosci. Rep.*, **8**: 497-502, 2008.
- Leiguarda R.C., and Marsden C.D. Limb apraxias: higher-order disorders of sensorimotor integration. *Brain*, **123** (5): 860-879, 2000.
- Leff A.P., Schofield T.M., Crinion J.T., Seghier M.L., Grogan A., Green D.W., et al. The left superior temporal gyrus is a shared substrate for auditory short-term memory and speech comprehension: evidence from 210 patients with stroke. *Brain*, **132**: 3401-3410, 2009.
- Liepmann H. *Drei Aufsätze aus dem Apraxiegebiet*. Berlin, S. Karger Publ., 1908.
- Medina J., Kimberg D.Y., Chatterjee A., Coslett H.B. Inappropriate usage of the Brunner-Munzel test in recent voxel-based lesion-symptom mapping studies. *Neuropsychologia*, **48**: 341-343, 2010.
- Newman-Norlund R., van Schie H.T., van Hoek M.E., Cuijpers R.H., Bekkering H. The role of inferior frontal and parietal areas in differentiating meaningful and meaningless object-directed actions. *Brain Res.*, **1315**: 63-74, 2010.
- Noppeney U., Josephs O., Kiebel S., Friston K.J., Price C.J. Action selectivity in parietal and tem-

- poral cortex. *Cogn. Brain Res.*, **25** (3): 641-649, 2005.
- Ohgami Y., Matsuo K., Uchida N., Nakai T. An fMRI study of tool-use gestures: body part as object and pantomime. *Neuroreport*, **15** (12): 1903-1906, 2004.
- Pazzaglia M., Smania N., Corato E., Aglioti S.M. Neural underpinnings of gesture discrimination in patients with limb apraxia. *J. Neurosci.*, **28**: 3030-3041, 2008.
- Prabhakaran S., Zarah E., Riley C., Speizer A., Chong J.Y., Lazar R.M., et al. Inter-individual variability in the capacity for motor recovery after ischemic stroke. *Neurorehabil. Neural Repair*, **22**: 64-71, 2008.
- Price C.J. and Friston K.J. Degeneracy and cognitive anatomy. *Trends Cogn. Sci.*, **6**: 416-421, 2002.
- Price C.J., Seghier M.L., Leff A.P. Predicting language outcome and recovery after stroke: the FLORAS system. *Nat. Rev. Neurol.*, **6**: 202-210, 2010.
- Quallo M.M., Price C.J., Ueno K., Asamizuya T., Cheng K., Lemon R.N., et al. Gray and white matter changes associated with tool-use learning in macaque monkeys. *Proc. Natl. Acad. Sci. USA*, **106**: 18379-18384, 2009.
- Richardson F.M., Thomas M.S., Price C.J. Neuronal activation for semantically reversible sentences. *J. Cogn. Neurosci.*, **22**: 1283-1298, 2010.
- Rorden C., Karnath H.O., Bonilha L. Improving lesion-symptom mapping. *J. Cogn. Neurosci.*, **19**: 1081-1088, 2007.
- Rorden C., Fridriksson J., Karnath H.O. An evaluation of traditional and novel tools for lesion behavior mapping. *Neuroimage*, **44**: 1355-1362, 2009.
- Rothi L.J., Heilman K.M., Watson R.T. Pantomime comprehension and ideomotor apraxia. *J. Neurol. Neurosurg. Psychiatry*, **48** (3): 207-210, 1985.
- Rudrauf D., Mehta S., Bruss J., Tranel D., Damasio H., Grabowski T.J. Thresholding lesion overlap difference maps: application to category-related naming and recognition deficits. *Neuroimage*, **41**: 970-984, 2008.
- Seghier M.L., Friston K.J., Price C.J. Detecting subject-specific activations using fuzzy clustering. *Neuroimage*, **36**: 594-605, 2007.
- Seghier M.L., Ramlakhansingh A., Crinion J., Leff A., Price C.J. Lesion identification using unified segmentation-normalisation models and fuzzy clustering. *Neuroimage*, **41**: 1253-1266, 2008.
- Skipper J.I., Goldin-Meadow S., Nusbaum H.C., Small S.L. Speech-associated gestures, Broca's area, and the human mirror system. *Brain Lang.*, **101**: 260-277, 2007.
- Stein J., Harvey R.L., Macko R.F., Winstein C.J., Zorowitz R.D. *Stroke, Recovery and Rehabilitation*. New York, Demos Medical Publishing, 2009.
- Swinburn K., Porter G., Howard D. *The comprehensive aphasia test*. New York, Psychology Press, 2004.
- Tranel D., Kemmerer D., Adolphs R., Damasio H., Damasio A. Neural correlates of conceptual knowledge for actions. *Cogn. Neuropsychol.*, **20**: 409-432, 2003.
- Van Peppen R.P., Kwakkel G., Wood-Dauphinee S., Hendriks H.J., Van der Wees P.J., Dekker J. The impact of physical therapy on functional outcomes after stroke: what's the evidence? *Clin. Rehabil.*, **18**: 833-862, 2004.