

Diffusion Tensor Imaging in Schizophrenia

Monte S. Buchsbaum, Joseph Friedman, Bradley R. Buchsbaum, King-Wai Chu, Erin A. Hazlett, Randall Newmark, Jason S. Schneiderman, Yuliya Torosjan, Cheuk Tang, Patrick R. Hof, Daniel Stewart, Kenneth L. Davis, and Jack Gorman

Background: Alignment of white matter axons as inferred from diffusion tensor imaging has indicated changes in schizophrenia in frontal and frontotemporal white matter.

Methods: Diffusion tensor anisotropy and anatomical magnetic resonance images were acquired in 64 patients with schizophrenia and 55 normal volunteers. Anatomical images were acquired with a magnetization prepared rapid gradient echo sequence, and diffusion tensor images used a pulsed gradient spin-echo acquisition. Images were aligned and warped to a standard brain, and anisotropy in normal volunteers and patients was compared using significance probability mapping.

Results: Patients showed widespread areas of reduced anisotropy, including the frontal white matter, the corpus callosum, and the frontal longitudinal fasciculus.

Conclusions: These findings, which are consistent with earlier reports of frontal decreases in anisotropy, demonstrate that the effects are most prominent in frontal and callosal areas and are particularly widespread in frontal white matter regions.

Key Words: Schizophrenia, diffusion tensor imaging, magnetic resonance imaging, frontal lobe, white matter, prefrontal function

Alterations in connectivity among brain regions such as the frontal lobe, basal forebrain, and limbic system have been proposed as network deficits in schizophrenia (see recent reviews: Benes 2000; Bunney and Bunney 2000; Carlsson 2001; Grace 2000; Heimer 2000; Middleton and Strick 2000). The multiregional aspects of the hypothesized problems in connectivity implicate a possible deficit in white matter that could lead to the rerouting or interruption of a number of specific brain circuits. An abnormality in the large white matter center of the frontal lobe (about 12% of total cerebral volume [Schoenemann et al 2005]) and the anterior limb of the internal capsule, where thalamic and striatal axons course, could be associated with deficits in the function of these circuits. A global deficit in myelin in schizophrenia (Hakak et al 2001; Davis et al 2003) might also produce a pattern of distributed multiregional deficits compatible with the complex—not clearly localizing—behavioral and cognitive disorganization in schizophrenia. Alteration in numbers, distribution, and ultrastructural integrity of oligodendrocytes, key white matter components, has recently been reported in the prefrontal cortex in schizophrenia (Hof et al 2003; Uranova et al 2001, 2004; Vostrikov et al 2004).

To investigate white matter circuitry, we applied diffusion tensor magnetic resonance imaging (MRI) to a small group of patients with schizophrenia ($n = 5$) and found reduced organization of white matter, as inferred from anisotropy, in the frontal lobe and anterior limb of the internal capsule (Buchsbaum et al 1998), a finding replicated by Lim et al (1999). Frontal decreases in anisotropy in schizophrenia have been confirmed and extended in other reports (Ardekani et al 2003; Hubl et al 2004;

Kitamura et al 2005; Kumra et al 2004; Minami et al 2003; Szeszko et al 2005). In some reports, frontal lobe and fronto-temporal tracts including the arcuate fasciculus (Burns et al 2003), anterior cingulum bundle (Kubicki et al 2003; Sun et al 2003), and uncinate fasciculus (Kubicki et al 2002) were found to show low anisotropy; by contrast, no white matter area emerged as significantly low in studies of 14 (Foong et al 2002) and 10 schizophrenic (Steel et al 2001) patients. Lower right inferior frontal anisotropy was observed in more aggressive men with schizophrenia ($n = 14$) (Hoptman et al 2002). Generalized global fractional anisotropy reduction ($n = 20$) has also been reported (Agartz et al 2001). Small sample size, evaluation of only a single tract, lack of statistical control of age-related variation, and use of protected p levels in what are actually replication studies have diminished potential agreement among studies. In the current report, the largest group of schizophrenia patients studied with diffusion tensor imaging to date was assessed with higher field strength imaging, anatomical image co-registration and distortion correction, and age covariance analysis of the entire brain.

Methods and Materials

Subjects

Patients with schizophrenia were recruited from inpatient, outpatient, day treatment, and vocational rehabilitation services at Mount Sinai Hospital (New York), Pilgrim Psychiatric Center (W. Brentwood, New York), Bronx Veterans Affairs Medical Center (Bronx, New York), Hudson Valley Veterans Affairs Medical Center (Montrose, New York), and Queens Hospital Center (Jamaica, New York) after approvals by each institutional review board and informed consent was obtained from each subject. There were a total of 119 subjects scanned, 55 normal volunteers (32 men, 23 women, mean age 42.4 years, SD = 19.7, range 18–80) and 63 patients with schizophrenia (44 men and 19 women, mean age 41.7 years, SD = 12.5, range 20–73) without any significant differences in age [$t(116) = .24, p = .8$] or gender (Yates corrected chi-square, 1.27, $p = .26$). The inclusion criteria were as follows: 1) a DSM-IV diagnosis of schizophrenia on the basis of the Comprehensive Assessment of Symptoms And History (CASH; Andreasen et al 1992), and 2) age of 18–80 years. Healthy comparison subjects who did not meet criteria for a DSM-IV axis I disorder (by CASH interview) were recruited from the New York area and were matched for age and gender to the patients. Subjects were excluded if they had: 1) a positive urine

From the Neuroscience Positron Emission Tomography Laboratory (MSB, JF, K-WC, EAH, RN, JSS, YT, CT, PRH, DS, KLD, JG), Department of Psychiatry, Mount Sinai School of Medicine, New York, New York; and the National Institute of Mental Health Clinical Brain Disorders Branch (BRB), Bethesda, Maryland.

Address reprint requests to Monte S. Buchsbaum, M.D., Mount Sinai School of Medicine, Box 1505, 1 Gustave Levy Place, New York, NY 10029; E-mail: monte.buchsbaum@mssm.edu.

Received June 24, 2005; revised November 9, 2005; accepted November 15, 2005.

screen for drugs of abuse, 2) a medical diagnosis that might produce white matter changes (e.g., HIV, multiple sclerosis), 3) a brain disorder that might produce cognitive impairment or behavioral symptoms (e.g., head injury, cerebrovascular disease), 4) an unstable medical condition (e.g., poorly controlled diabetes or hypertension, symptomatic coronary artery disease), or 5) lifetime history of substance dependence meeting DSM-IV criteria or evidence of substance abuse (DSM-IV criteria) in the past year. Each subject was carefully screened with a medical history, physical examination, and laboratory studies (including complete blood count, routine chemistry, liver enzymes, thyroid function tests, and urine toxicology screen) to ensure they fulfilled the inclusion criteria.

The healthy comparison group contained 49.1% Caucasian, 30.9% African American, and 14.5% Hispanic subjects as compared with 31.8% Caucasians, 46.1% African American, and 22.1% Hispanic subjects in the schizophrenia group. The healthy comparison group was significantly better educated (mean years of education = 15, SD = 2.3) than the patient group (mean years of education = 12.2, SD = 1.9, [$t(116) = 7.4, p < .05$]) and more likely to be married (5 of 64 patients, 20 of 55 healthy subjects, chi-square, $p < .001$). At the time of scanning, 4.8% of the patients were unmedicated, 17.5% were receiving typical antipsychotics, 59.2% were receiving atypical antipsychotics (risperi-

done, olanzapine, ziprasidone, quetiapine, aripiprazole), and 17.5% were receiving clozapine. The average age of illness onset for the patients was 23.5 years (SD = 6.9; mean illness duration 18.2 years), and they demonstrated, as assessed by the Positive and Negative Syndrome Scale (PANSS), a modest severity of positive (mean PANSS Positive subscale score = 15, SD = 4.5), negative (mean PANSS Negative subscale score = 17.3, SD = 5.9) (Kay et al 1987), and total symptoms (mean 32.7, SD = 10.2). Three patients were left-handed, and four normal volunteers were left-handed. Of the 63 patients, 7 had onset within the past 2 years and the remainder had an earlier onset; thus the majority were chronic patients.

Image Acquisition

Anatomical images were acquired (3.0T Siemens Allegra; typical scanning time 50 minutes) with a magnetization prepared rapid gradient echo (MP-RAGE) sequence with the following parameters: pixel size = .82 × .82 × .82 mm, field of view = 210 mm, repetition time = 2500 ms, echo time = 4.38, T1 = 1100 ms, flip angle = 8°. Diffusion tensor images were acquired with a pulsed gradient spin-echo sequence with the following parameters: 28 3-mm-thick slices with 12 gradient directions. Images were processed with our own Matlab routines to produce fractional anisotropy (FA) images.

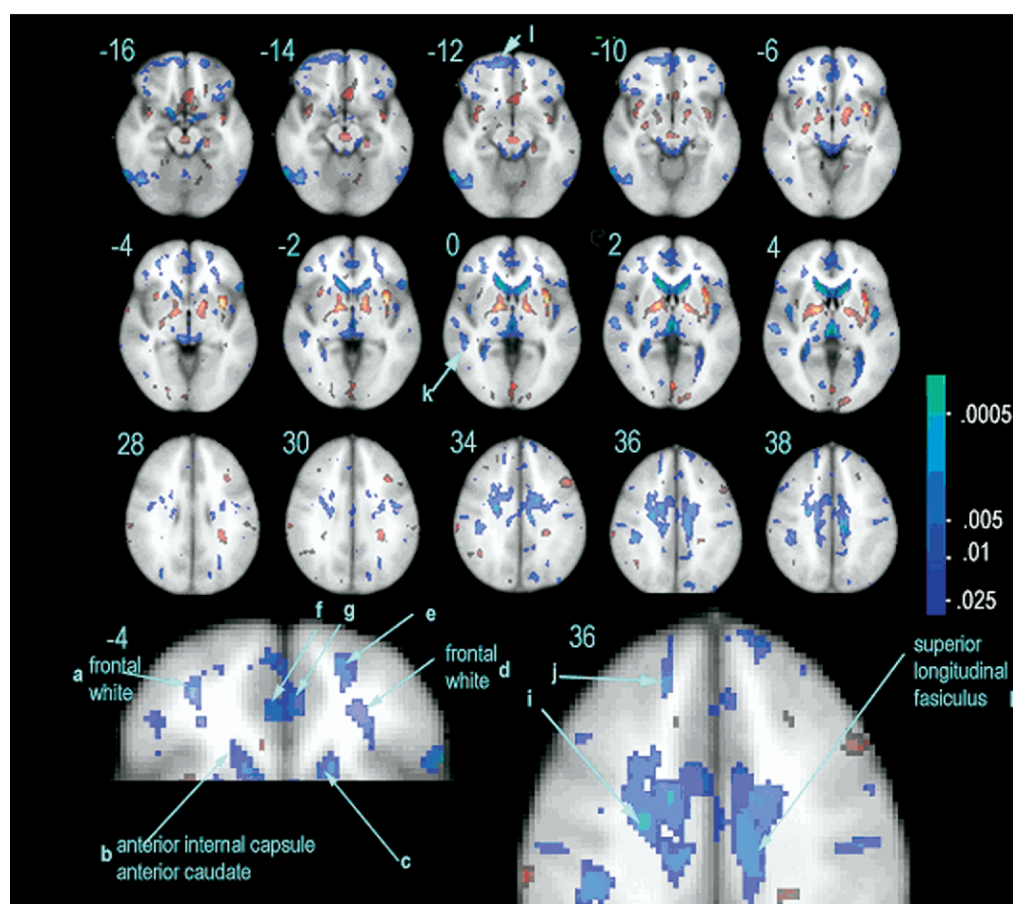


Figure 1. Anisotropy decrease in patients with schizophrenia. Top three rows show survey of brain slices 4.8 mm apart with Montreal Neurological Institute brain as background and colored patches indicating t -tests comparing normal subjects and patients with schizophrenia. Slices are presented in two series, from $z = -16$ to $z = +4$ (top two rows) and slices $z = +28$ to $z = +38$ (third row). Blue-light-blue-white indicates patients with lower anisotropy than normal volunteers with threshold set to $p < .05$, one-tailed, and range $p < .05$ (blue) to $p < .0005$ (light green). Effect sizes are .62, .48, .43, and .36 for $p < .0005$, .005, .01, and .025, respectively. Bottom row shows regions predicted in advance on the basis of earlier studies and located in frontal white matter and superior longitudinal white matter. Red regions are patients > control subjects. Letter labels are identified in Table 1.

Image Processing

Images were converted to ANALYZE format and processed with AIR 5.1 (Woods et al 1992). Anatomical images were aligned to the Montreal Neurological Institute (MNI) standard image with a six-parameter rigid-body transformation, and then a nonlinear warp was used to morph the brains to the standard brain. The diffusion tensor anisotropy images were first aligned to each individual's anatomical image. Next, the transformation matrix for the non-linear warping obtained previously for the anatomical image was applied to the diffusion tensor FA images.

Image Statistics

We computed *t*-test images with our own R language program. The effect of age was removed by expressing values as residual scores from the linear age/anisotropy line. We also conducted supplementary analyses, removing both linear and quadratic age effects. Significance probability images were expressed as one-tailed $p < .05$ threshold images with a color bar to indicate $p < .05$ to $p < .005$ for direct replication comparison with our own and other studies cited in the introduction and in particular with our earlier reported finding of low anisotropy in the left dorsolateral frontal cortex (Buchsbaum et al 1998). In exploratory studies, it is conventional for significance probability mapping (SPM) images to be thresholded at $p < .005$. Because we were seeking both to confirm a body of earlier reported findings with a regionally specific *a priori* hypothesis and to explore the entire brain, we adopted a combined statistical approach, presenting the p level as a continuous variable from $p < .05$, one-tailed for replication to $p < .0005$ for exploration.

Results

Areas of statistically significant, decreased anisotropy in patients with schizophrenia were distributed widely in frontal and centrum semiovale white matter, the corpus callosum, and the anterior internal capsule (Figure 1 and Table 1). The posterior limb of the internal capsule had relatively high anisotropy (Figure 1). A magnified view (Figure 2) shows the detailed placement of these deficits with both the mean anisotropy and MNI anatomical brain backgrounds. The relatively decreased anisotropy in the anterior limb of the internal capsule is at its most anterior end and extends forward into the highly anisotropic pathway termed the "anterior thalamic radiations" (Wakana et al 2004). Thus, the current finding of low prefrontal anisotropy in an independent and much larger sample replicated the earlier findings reviewed in the introduction (Figure 3). Sagittal views (Figure 4) locate anterior corpus callosum and cingulate gyrus decreases in patients with schizophrenia. The areas of greatest effect (green and light green, $p < .005$ to $.00005$) appear to be in the regions of the anterior thalamic radiations, prefrontal white matter, and superior longitudinal fasciculus. Group changes were essentially unchanged when both linear and quadratic age effects were removed. When individuals over 60 years old were removed, the frontal predominance of low anisotropy findings in schizophrenia was enhanced, and this was especially true of the frontal white matter (Figure 5).

Discussion

Our results in this sample are consistent with results from our two earlier independent samples indicating reduced anisotropy in the frontal white matter of patients with schizophrenia (Figure 3). The voxel-by-voxel maps show significant differences in the

Table 1. Regions With Lower Anisotropy in Patients With Schizophrenia Than Normal Volunteers

Key	z	Structure	x	y	z	t
f	−4	Cingulate Gyrus	−2	42	−4	−2.40
g	−4	Cingulate Gyrus	4	44	−4	−2.72
h	38	Cingulate Gyrus	10	20	38	−4.09
l	−12	Frontal White	−12	60	−12	−2.66
l	−10	Frontal White	−8	60	−10	−3.04
a	−4	Frontal White	−32	50	−4	−3.30
d	−4	Frontal White	26	44	−4	−2.40
e	−4	Frontal White	26	60	−4	−2.98
j	36	Frontal White	18	42	36	−2.72
b	−4	Int. Cap. Ant.	−14	24	−4	−3.04
c	−4	Int. Cap. Ant.	16	24	−4	−2.92
i	30	Sup. Long. Fasc.	−32	2	30	−2.53
i	34	Sup. Long. Fasc.	−26	−6	34	−3.44
h	36	Sup. Long. Fasc.	10	20	36	−3.50
i	36	Sup. Long. Fasc.	−24	−4	36	−3.57
i	38	Sup. Long. Fasc.	26	−6	38	−3.24
k	−2	Temporal White	50	−28	−2	−3.11
k	2	Temporal White	50	−42	2	−2.66
k	0	Temporal White	50	−38	0	−2.98

Designations a–l correspond to Figure 1, a–j are shown on key diagrams at the bottom, and k–l in the three top rows. The z level is given for additional regions on adjacent z levels; $t = 1.66, p < .05$; $t = 1.98, p < .025$; $t = 2.36, p < .01$; $t = 2.62, p < .005$; $t = 3.37, p = .0005$. Footnoted are the Talairach daemon (Lancaster et al 2000) locations obtained for the exact coordinates of the highest *t*: Int., internal; cap, capsule; ant., anterior; sup., superior; long., longitudinal; fasc., fasciculus.

a, −4 middle frontal gyrus white matter
b, −4 subgyral white matter, anterior cingulate white matter, extranuclear white matter
c, −4 subgyral white matter, extranuclear white matter, anterior cingulate white matter
d, −4 middle frontal gyrus, subgyral white matter
e, −4 superior frontal gyrus white matter
f, −4 anterior cingulate gyrus gray, white
g, −4 anterior cingulate gyrus gray, white
h, 36 cingulate gyrus white matter, cingulate gyrus gray matter
h, 38 cingulate gyrus white matter
i, 36 frontal lobe subgyral white matter
i, 38 frontal lobe subgyral white matter, inferior frontal gyrus white matter
l, 34 frontal lobe subgyral white matter, middle frontal gyrus white matter
i, 30 frontal lobe subgyral white matter, precentral gyrus white matter, inferior frontal white matter
k, 0 temporal lobe white matter Brodmann area 22 (superior)
k, −2 middle temporal gyrus white matter, superior temporal gyrus white matter
k, −2 middle temporal gyrus white matter, Brodmann area 22
l, −12 superior frontal gyrus white matter, medial frontal gyrus white matter
l, −10 superior frontal gyrus white matter, gray matter Brodmann area 10

center of the frontal mass of white matter and in the anterior limb of the internal capsule. The bilateral placement of the regions of reduced anisotropy in the frontal white matter just anterior to the anterior limb of the internal capsule is consistent with a change in the organization of fibers linking the mediodorsal nucleus of the thalamus and prefrontal areas.

Our results are also comparable to earlier results by other investigators (Ardekani et al 2003; Hubl et al 2004; Kitamura et al 2005; Kumra et al 2004; Szeszko et al 2005). There are some parallels as well to previous reports that failed to find low

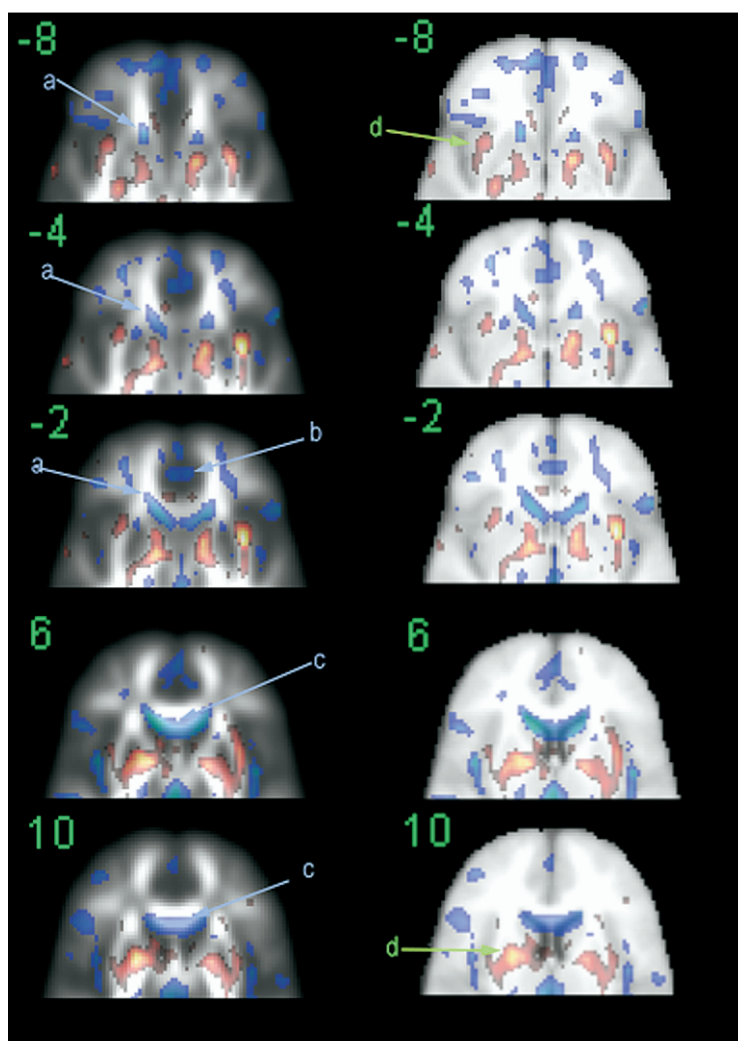


Figure 2. Frontal region anisotropy maps. Significance probability maps as in Figure 1 presented on backgrounds of average anisotropy (left column) and average co-registered anatomical magnetic resonance imaging (right column). Talairach z levels are given as green numerals. Note regions in anterior end of internal capsule and adjacent anterior thalamic radiations and anterior tip of caudate nucleus (A), cingulate gyrus (B), and corpus callosum (C). Areas of increased anisotropy include the insula (D, slice -8) and the putamen and globus pallidus (D, slice $+10$).

anisotropy in the prefrontal area. For example, Foong et al (2002) used a threshold of $t = 3.09$, which corresponds to $p < .001$, and found no significant areas of anisotropy that reached this threshold. However, they appropriately published x, y, z coordinates of uncorrected p values. For coordinates 11,17,0 (caudate nucleus as identified by Talairach daemon), they observed $p = .009$, and we obtained $t = -3.46$, $p < .0005$. This area extends in our data into what is termed sub-lobar extranuclear white matter as far anteriorly as coordinates 18,30,0, an area just anterior to the anterior limb of the internal capsule. We found the superior longitudinal fasciculus to have

low anisotropy in schizophrenia with the effect somewhat larger in the left hemisphere than in the right, not inconsistent with earlier asymmetry analyses (Park et al 2004). Regions that have low anisotropy in our study were generally found to lose the normal asymmetrical pattern in patients with schizophrenia (including the anterior limb of the internal capsule and superior longitudinal fasciculus) in a left–right hemisphere comparison study (Park et al 2004), but Park et al did not present statistical maps directly comparing normal volunteers and patients. Because few of our patients with schizophrenia were left-handed, we could not evaluate the relationship

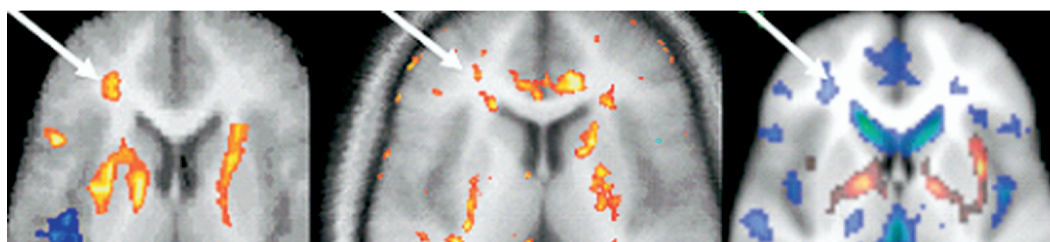


Figure 3. Three independent diffusion tensor anisotropy maps comparing location of region where anisotropy is low. Left: $n = 11$, red = patients $<$ control subjects (Buchsbaum et al 1998); middle: $n = 72$, red = patients $<$ control subjects, presented at American Psychiatric Association 2002, no overlap with 1998 sample. Right: current sample, $n = 119$, blue = patients $<$ control subjects. Note that 1999 and 2004 samples use red to indicate that patients with schizophrenia are lower than normal, whereas the current sample uses blue. Arrow points to 26, 37, 12, and 24, 43, 4 in Talairach coordinates.

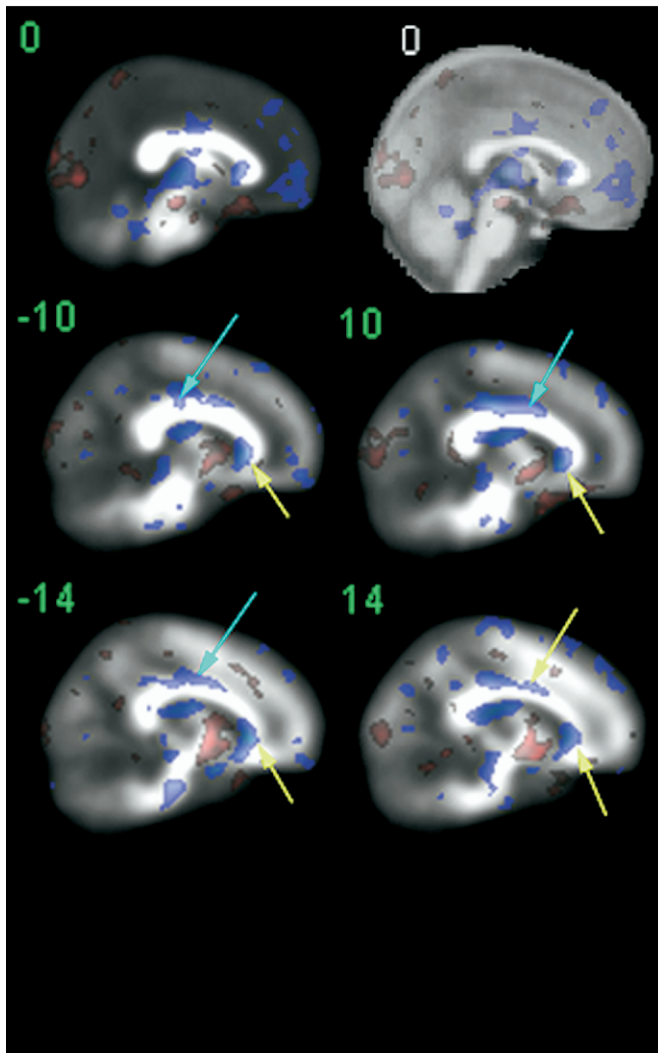


Figure 4. Sagittal view at midline and 10 and 14 mm. Background is mean diffusion tensor anisotropy except for midline (0 mm) section in upper right, which is magnetization prepared rapid gradient echo. Color bar is blue for schizophrenia patients with lower values than normal volunteers, as in Figures 1 and 2. Aqua arrows indicate corpus callosum and adjacent cingulum. Yellow arrows indicate genu of corpus callosum and in the right corpus callosum the deepest extent of the significant area. Patients show higher anisotropy than normal volunteers primarily in posterior regions (occipital lobe and in the striatum).

between hemispheric dominance and anisotropy change. We did not confirm anisotropy alteration in the amygdala (Kalus et al 2005) (see our Figure 1, $z = -12$), but actual amygdala tracing on the co-registered MRI might be more accurate. Our data also partly agree with earlier reported significance probability maps that demonstrated low anisotropy in the anterior corpus callosum in schizophrenia (Agartz et al 2001), but we did not replicate findings of low anisotropy in the splenium of the corpus callosum or occipital white matter. The decrease in the uncinate fasciculus in schizophrenia (Kubicki et al 2002) is partly supported in our results in a small area at its anterior end (see Figure 1, slice $z = -12$ matching the standard atlas [Talairach and Tournoux 1988]), but its more posterior and lateral part might actually show increased anisotropy in our sample. If the complex right-angle shape of this fasciculus is rotated in space or its topography disturbed, both increases

and decreases in anisotropy might well result, and detailed tract-tracing here is needed to resolve the question.

In further exploration of the relationship of our current data to earlier investigations, we also examined the x, y, z coordinates corresponding to Figure 3 that were kindly furnished by the authors of an earlier report (Ardekani et al 2003) but were unable to confirm them in our data set with the one-tailed confirmatory t -test [(a) $(-37, 51, 33)$, (b) $(16, 21, 28)$, (c) $(3, 8, 27)$, (d) $(25, 55, 16)$, (e) $(2, 38, 14)$, (f) $(29, 23, 8)$, (g) $(47, 26, 11)$, and (h) $(24, 17, 20)$].

Changes in anisotropy do not seem to be related to global white matter loss in schizophrenia. Findings of structural MRI have included a greater than normal volume of global white matter in schizophrenia (Marcelis et al 2003), a lesser degree of volume reduction in white matter than in gray matter (Mitelman et al 2003), and no reduction in prefrontal and temporal white matter (Yamasue et al 2004)—areas where we observe low anisotropy in schizophrenia with diffusion tensor imaging. Dysfunction might not necessarily be related to a reduction in white matter, per se, because patients with hallucinations might have greater temporal lobe white matter volume (Shin et al 2005). However, some small regions of low anisotropy identified in our study overlap with white matter regions previously identified in structural MRI studies as smaller in patients with schizophrenia, including the anterior limb of the internal capsule (Suzuki et al 2004) and the genu of the corpus callosum (see review elsewhere [Downhill et al 2000]).

Some limitations of our study are: the inclusion of a preponderance of medicated and chronic patients; technical error, including inaccuracy in co-registration, subject movement, and field distortion; wide age range; and the lack of co-registered functional images (e.g., positron emission tomography, functional MRI) to provide a source of independent validation of the findings of diffusion tensor imaging.

Although diffusion tensor abnormalities in unmedicated patients were revealed in the earliest study in schizophrenia (Buchsbaum et al 1998), there remains the possibility that antipsychotic medications might influence the pruning, disconnection, or imperfect repair of white matter in such a way as to cause changes in anisotropy. White matter volume decreases have been found in a serial volumetric study after treatment (Christensen et al 2004). In our sample, only three patients were unmedicated, and the history of the remainder includes individuals receiving two or more neuroleptics, typical and atypical neuroleptics simultaneously, and typical and atypical neuroleptics serially; this natural history really precludes rigorous assessment of drug effects. Only further follow-up studies of unmedicated patients can definitively answer this question. Alcohol use can cause brain shrinkage and influence anisotropy (Pfefferbaum and Sullivan 2005), but our patients were screened for alcoholism. Brain edema and other nonspecific brain changes (as inferred from T2 images), potentially associated with hydration side effects of neuroleptics, were uncorrelated with anisotropy in patients with schizophrenia (Pfefferbaum et al 1999). Age effects are unlikely to fully explain our group differences, because: 1) patients and healthy subjects were matched on age, 2) statistical maps of group differences show statistically age-corrected differences, 3) removal of age-quadratic regression curves changed data little, and 4) omission of subjects 60-years-old and over strengthened rather than weakened frontal anisotropy differences. A systematic examination of age-regression linear slope differences for specific tracts might require somewhat larger samples.

Magnified views of registered MNI MRI and the diffusion tensor images suggest a good alignment and distortion correction between the image pairs, but complex nonlinearities might

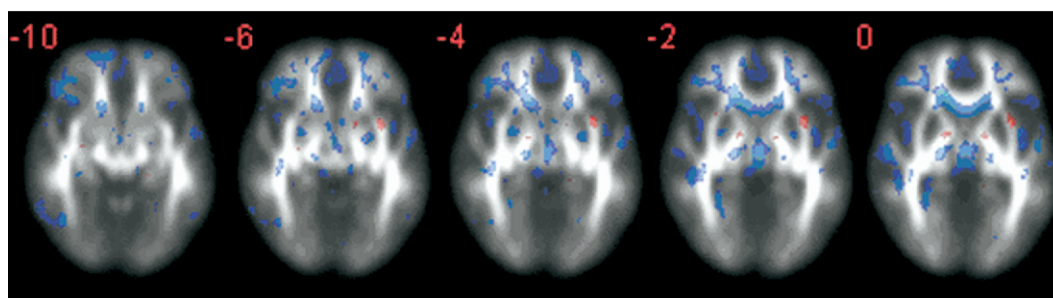


Figure 5. Anisotropy in subgroup containing only subjects < 60 years of age. Slice levels to match center section of Figure 1 are presented. Threshold is set at $t = -2.32$, $p < .01$, one-tailed.

degrade the quality. These would tend to increase anisotropy variance and create Type II statistical error. The alignment of the significant areas with maxima in the anterior thalamic radiations as well as with the exact Talairach coordinates reported in earlier studies that were done with row-and-column linear adjustment of anisotropy and anatomical images suggests that these sources of error do not obscure group differences. Low anisotropy in the ventricles is a potential artifact, and for that reason, both anisotropy and anatomical image backgrounds are presented to help clarify these boundaries.

The pattern of decreases in anisotropy observed in this large sample of patients with schizophrenia confirms and extends earlier reports in smaller groups of patients. Taken together, the findings suggest that prefrontal–thalamic interhemispheric prefrontal and fronto-occipital tracts might be especially affected, although white matter tracts in the uncinate and other temporal lobe areas might also be important. The data are apparently consistent with circuit abnormalities in which white matter fibers are less well aligned in patients with schizophrenia than in normal control subjects. This might result from precise topographic patterns not being fully developed, fully pruned, or normally routed; only combinations of tract tracing, longitudinal, and high-risk studies can fully distinguish these possibilities. However, the widespread distribution of significant differences visible in Figure 1 could not implausibly be used to argue for some relatively global deficit of white matter myelination or structure. The more frontal concentration and involvement of fronto-occipital tracts tends to support a more restricted region of abnormality, but studies of white matter with magnetic resonance spectroscopy and magnetization transfer ratio techniques will help to address this important question.

This work was supported by P50 MH 66392-01 (to KLD, MSB, and PRH), MH60023 (MSB), VISN3 MIRECC (Dr. Siever), and the General Clinical Research Center, M01-RR-00071.

- Agartz I, Andersson JL, Skare S (2001): Abnormal brain white matter in schizophrenia: A diffusion tensor imaging study. *Neuroreport* 12:2251–2254.
- Andreasen N, Flaum M, Arndt S (1992): The Comprehensive Assessment of Symptoms and History (CASH): An instrument for assessing diagnosis and psychopathology. *Arch Gen Psychiatry* 49:615–623.
- Ardekani BA, Nierenberg J, Hoptman MJ, Javitt DC, Lim KO (2003): MRI study of white matter diffusion anisotropy in schizophrenia. *Neuroreport* 14: 2025–2029.
- Benes FM (2000): Emerging principles of altered neural circuitry in schizophrenia. *Brain Res Brain Res Rev* 31:251–69.
- Buchsbaum MS, Tang CY, Peled S, Gudbjartsson H, Lu D, Hazlett EA, et al (1998): MRI white matter diffusion anisotropy and PET metabolic rate in schizophrenia. *NeuroReport* 9:425–430.

- Bunney WE, Bunney BG (2000): Evidence for a compromised dorsolateral prefrontal cortical parallel circuit in schizophrenia. *Brain Res Brain Res Rev* 31:138–146.
- Burns J, Job D, Bastin ME, Whalley H, Macgillivray T, Johnstone EC, Lawrie SM (2003): Structural disconnectivity in schizophrenia: A diffusion tensor magnetic resonance imaging study. *Br J Psychiatry* 182:439–443.
- Carlsson A (2001): A paradigm shift in brain research. *Science* 294:1021–1024.
- Christensen J, Holcomb J, Garver DL (2004): State-related changes in cerebral white matter may underlie psychosis exacerbation. *Psychiatry Res* 130:71–78.
- Davis KL, Stewart DG, Friedman JI, Buchsbaum M, Harvey PD, Hof PR, et al (2003): White matter changes in schizophrenia: evidence for myelin-related dysfunction. *Arch Gen Psychiatry* 60:443–456.
- Downhill JE, Jr., Buchsbaum MS, Wei T, Spiegel-Cohen J, Hazlett EA, Haznedar MM, et al (2000): Shape and size of the corpus callosum in schizophrenia and schizotypal personality disorder. *Schizophr Res* 42:193–208.
- Foong J, Symms MR, Barker GJ, Maier M, Miller DH, Ron MA (2002): Investigating regional white matter in schizophrenia using diffusion tensor imaging. *Neuroreport* 13:333–336.
- Grace AA (2000): Gating of information flow within the limbic system and the pathophysiology of schizophrenia. *Brain Res Brain Res Rev* 31:330–341.
- Hakak Y, Walker JR, Li C, Wong WH, Davis KL, Buxbaum JD, et al (2001): Genome-wide expression analysis reveals dysregulation of myelination-related genes in chronic schizophrenia. *Proc Natl Acad Sci U S A* 98:4746–4751.
- Heimer L (2000): Basal forebrain in the context of schizophrenia. *Brain Res Brain Res Rev* 31:205–35.
- Hof PR, Haroutunian V, Friedrich VL Jr., Byne W, Buitron C, Perl DP, Davis KL (2003): Loss and altered spatial distribution of oligodendrocytes in the superior frontal gyrus in schizophrenia. *Biol Psychiatry* 53:1075–1085.
- Hoptman MJ, Volavka J, Johnson G, Weiss E, Bilder RM, Lim KO (2002): Frontal white matter microstructure, aggression, and impulsivity in men with schizophrenia: A preliminary study. *Biol Psychiatry* 52:9–14.
- Hubl D, Koenig T, Strik W, Federspiel A, Kreis R, Boesch C, et al (2004): Pathways that make voices: White matter changes in auditory hallucinations. *Arch Gen Psychiatry* 61:658–668.
- Kalus P, Slotboom J, Gallinat J, Wiest R, Ozdoba C, Federspiel A, et al (2005): The amygdala in schizophrenia: A trimodal magnetic resonance imaging study. *Neurosci Lett* 375:151–156.
- Kay SR, Fiszbein A, Opler LA (1987): The positive and negative syndrome scale (PANSS) for schizophrenia. *Schizophr Bull* 13:261–276.
- Kitamura H, Matsuzawa H, Shioiri T, Someya T, Kwee IL, Nakada T (2005): Diffusion tensor analysis in chronic schizophrenia. A preliminary study on a high-field (3.0T) system. *Eur Arch Psychiatry Clin Neurosci* 255:313–318.
- Kubicki M, Westin CF, Maier SE, Frumin M, Nestor PG, Salisbury DF, et al (2002): Uncinate fasciculus findings in schizophrenia: a magnetic resonance diffusion tensor imaging study. *Am J Psychiatry* 159:813–820.
- Kubicki M, Westin CF, Nestor PG, Wible CG, Frumin M, Maier SE, et al (2003): Cingulate fasciculus integrity disruption in schizophrenia: A magnetic resonance diffusion tensor imaging study. *Biol Psychiatry* 54:1171–1180.
- Kumra S, Ashtari M, McMeniman M, Vogel J, Augustin R, Becker DE, et al (2004): Reduced frontal white matter integrity in early-onset schizophrenia: A preliminary study. *Biol Psychiatry* 55:1138–1145.

- Lancaster JL, Woldorff MG, Parsons LM, Liotti M, Freitas CS, Rainey L, et al (2000): Automated Talairach atlas labels for functional brain mapping. *Hum Brain Mapp* 10:120–131.
- Lim KO, Hedehus M, Moseley M, de Crespigny A, Sullivan EV, Pfefferbaum A (1999): Compromised white matter tract integrity in schizophrenia inferred from diffusion tensor imaging. *Arch Gen Psychiatry* 56:367–734.
- Marcelis M, Suckling J, Woodruff P, Hofman P, Bullmore E, van Os J (2003): Searching for a structural endophenotype in psychosis using computational morphometry. *Psychiatry Res* 122:153–167.
- Middleton FA, Strick PL (2000): Basal ganglia and cerebellar loops: Motor and cognitive circuits. *Brain Res Brain Res Rev* 31:236–250.
- Minami T, Nobuhara K, Okugawa G, Takase K, Yoshida T, Sawada S, et al (2003): Diffusion tensor magnetic resonance imaging of disruption of regional white matter in schizophrenia. *Neuropsychobiology* 47:141–145.
- Mitelman SA, Shihabuddin L, Brickman AM, Hazlett EA, Buchsbaum MS (2003): MRI assessment of gray and white matter distribution in Brodmann's areas of the cortex in patients with schizophrenia with good and poor outcomes. *Am J Psychiatry* 160:2154–2168.
- Park HJ, Westin CF, Kubicki M, Maier SE, Niznikiewicz M, Baer A, et al (2004): White matter hemisphere asymmetries in healthy subjects and in schizophrenia: A diffusion tensor MRI study. *Neuroimage* 23:213–223.
- Pfefferbaum A, Sullivan EV (2005): Disruption of brain white matter microstructure by excessive intracellular and extracellular fluid in alcoholism: Evidence from diffusion tensor imaging. *Neuropsychopharmacology* 30:423–432.
- Pfefferbaum A, Sullivan EV, Hedehus M, Moseley M, Lim KO (1999): Brain gray and white matter transverse relaxation time in schizophrenia. *Psychiatry Res* 91:93–100.
- Schoenemann PT, Sheehan MJ, Glotzer LD (2005): Prefrontal white matter volume is disproportionately larger in humans than in other primates. *Nat Neurosci* 8:242–252.
- Shin SE, Lee JS, Kang MH, Kim CE, Bae JN, Jung G (2005): Segmented volumes of cerebrum and cerebellum in first episode schizophrenia with auditory hallucinations. *Psychiatry Res* 138:33–42.
- Steel RM, Bastin ME, McConnell S, Marshall I, Cunningham-Owens DG, Lawrie SM, et al (2001): Diffusion tensor imaging (DTI) and proton magnetic resonance spectroscopy (1H MRS) in schizophrenic subjects and normal controls. *Psychiatry Res* 106:161–170.
- Sun Z, Wang F, Cui L, Breeze J, Du X, Wang X, et al (2003): Abnormal anterior cingulum in patients with schizophrenia: A diffusion tensor imaging study. *Neuroreport* 14:1833–1836.
- Suzuki M, Zhou SY, Hagino H, Takahashi T, Kawasaki Y, Nohara S, et al (2004): Volume reduction of the right anterior limb of the internal capsule in patients with schizotypal disorder. *Psychiatry Res* 130:213–225.
- Szeszko PR, Ardekani BA, Ashtari M, Kumra S, Robinson DG, Sevy S, et al (2005): White matter abnormalities in first-episode schizophrenia or schizoaffective disorder: A diffusion tensor imaging study. *Am J Psychiatry* 162:602–605.
- Talairach J, Tournoux P (1988): *Co-Planar Stereotaxic Atlas of the Human Brain*. Stuttgart, Germany: Thieme.
- Uranova N, Orlovskaya D, Vikhrev O, Zimina I, Kolomeets N, Vostrikov V, Rachmanova V (2001): Electron microscopy of oligodendroglia in severe mental illness. *Brain Res Bull* 55:597–610.
- Uranova NA, Vostrikov VM, Orlovskaya DD, Rachmanova VI (2004): Oligodendroglial density in the prefrontal cortex in schizophrenia and mood disorders: A study from the Stanley Neuropathology Consortium. *Schizophr Res* 67:269–275.
- Vostrikov VM, Uranova NA, Rakhmanova VI, Orlovskaya DD (2004): [Lowered oligodendroglial cell density in the prefrontal cortex in schizophrenia]. *Zh Nevrol Psikhiatr Im S S Korsakova* 104:47–51.
- Wakana S, Jiang H, Nagae-Poetscher LM, van Zijl PC, Mori S (2004): Fiber tract-based atlas of human white matter anatomy. *Radiology* 230:77–87.
- Woods RP, Cherry SR, Mazziotta JC (1992): Rapid automated algorithm for aligning and reslicing PET images. *J Comput Assist Tomogr* 16:620–633.
- Yamasue H, Iwanami A, Hirayasu Y, Yamada H, Abe O, Kuroki N, et al (2004): Localized volume reduction in prefrontal, temporolimbic, and paralimbic regions in schizophrenia: An MRI parcellation study. *Psychiatry Res* 131:195–207.